



PATIENT

Abel Elliott

PRESENTING CLINICAL SIGNS

History: CXR revealed enlarged heart. No murmur. Previously came in for vomiting – resolved. On a grain-free diet.

SPECIES

Canine

RADIOGRAPHIC FINDINGS *NOTE: Images submitted for supplemental cardiac information only. Subjectively normal cardiac silhouette. No obvious evidence of CHF.

BREED

Pitbull

ELECTROCARDIOGRAPHIC FINDINGS *Note: Single lead ECGs are evaluated as a rhythm strip. Morphology/MEA cannot be definitively commented on.

A single lead ECG is available; 25mm/s, 10mm/mV. The average heart rate is 90bpm (range 83-100bpm). The rhythm is sinus in origin, with a p for every QRS complex and vice versa. The P and QRS morphologies are positive. No ectopic beats, pauses or other dysrhythmias observed. ECG diagnosis: Normal sinus rhythm with respiratory variation.

SEX

Male Neutered

ECHOCARDIOGRAM FINDINGS

2D, m-mode, color flow and doppler imaging is available. Normal mitral valve leaflets with no prolapse into the left atrial lumen. Trace mitral regurgitation with a normal left atrial dimension. Normal LV diameter with adequate myocardial function. The tricuspid valve appears normal with trace tricuspid regurgitation. Normal velocity. Normal right atrial and ventricular diameter and morphology indicating no overt evidence of pulmonary arterial hypertension. The pulmonic and aortic valves are normal in morphology and mobility. Normal pulmonic and aortic outflow velocities with laminar flow. No obvious aortic or pulmonic insufficiency. No pericardial or pleural effusion noted. No obvious cardiac masses.

AGE

7 years

WEIGHT

64lbs

CARDIAC CHART

CANINE CARDIAC PARAMETERS	MR VMAX (m/s)	TR VMAX (m/s)	LA/AO (Boon method)	LA/AO (Heart Base; Swe)	FS (%)	EF (%)	EPSS (cm)	
NORMAL PARAMETER	4.5-5.5	<2.7	1.3	<1.6	28-40	40-100	<0.6	
PATIENT	NM	2.0	1.2	1.3	31	76	0.6	
CANINE CARDIAC PARAMETERS	HR (BPM)	AV VMAX (m/s)	PV MAX (m/s)	BODY WEIGHT (kg)	LA 2D short axis Base view (cm)	LVIDd Avg; 2D and m-mode short axis (cm)	LVIDs Avg; 2D and m-mode short axis (cm)	
NORMAL PARAMETER	50-100	0.7-1.7	0.7-1.6	BELOW	BELOW	BELOW	BELOW	
PATIENT	100	1.3	0.9	29.0	2.4	4.7	3.2	
*Normal chamber parameters expressed as a mean value (SD)					3	1.27 (5.3)	2.46 (2.46)	1.36 (5.5)
BODY WEIGHT DEPENDENT PARAMETERS					5	1.40 (4.5)	2.74 (5.2)	1.60 (4.7)
<i>*Note: All measurements based upon multi-modal images and methods. An average value is reported.</i>					10	1.50 (3.8)	3.27 (3.5)	2.06 (3.1)
					15	1.83 (2.0)	3.71 (2.4)	2.43 (2.1)
					20	2.02 (1.9)	4.14 (2.2)	2.80 (2.0)
					25	2.18 (2.4)	4.48 (2.9)	3.10 (2.5)
					30	2.33 (3.3)	4.83 (3.9)	3.39 (3.4)
					35	2.48 (4.3)	5.17 (5.0)	3.69 (4.5)
					40	2.62 (5.2)	5.48 (6.1)	3.96 (5.4)
					50	2.88 (7.1)	6.07 (8.3)	4.46 (7.4)

Adapted from June Boon, Veterinary Echocardiography, 1998
Rishniw M and Hollis NE, J Vet Intern Med 2000; 14:429-435
Hansson et al, Vet Rad and Ultrasound 2002
Bonagura et al. Echocardiography: principles of interpretation, Vet Clin North Am 15:1177, 1995

INTERPRETED BY

Maggie Machen Lamy, DVM, DACVIM (Cardiology)

IMAGING PERFORMED BY

Kim Liedberg

HOSPITAL NAME

SVS Imaging WI

REFERRING VET

Dr. Baum

INVOICE

25160

DATE

7/5/22

**PATIENT**

Abel Elliott

SPECIES

Canine

BREED

Pitbull

SEX

Male Neutered

AGE

7 years

WEIGHT

64lbs

INTERPRETED BYMaggie Machen Lamy,
DVM, DACVIM
(Cardiology)**IMAGING PERFORMED BY**

Kim Liedberg

HOSPITAL NAME

SVS Imaging WI

REFERRING VET

Dr. Baum

INVOICE

25160

DATE

7/5/22

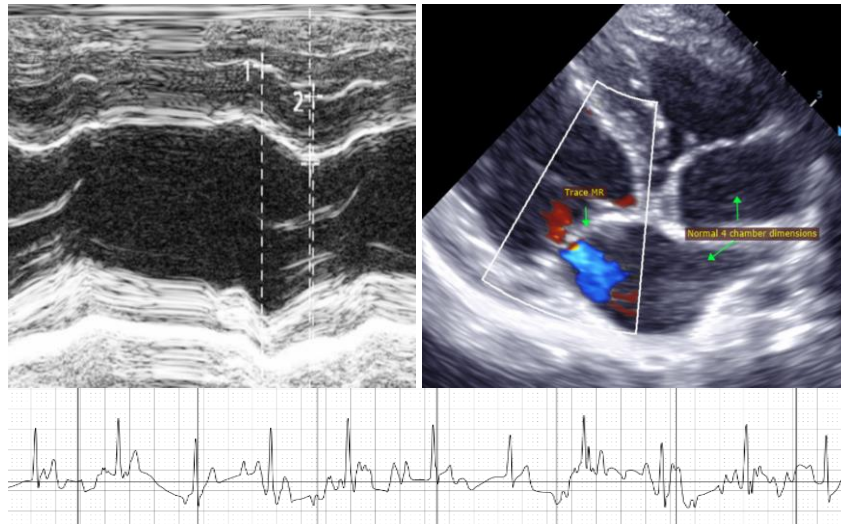
INTERPRETATION OF THE FINDINGS & FURTHER RECOMMENDATIONS

Overtly normal cardiac dimensions and function, with no obvious dysfunction or dilation of the left heart. MR and TR are considered physiologic in the absence of a murmur. No significant valvular leaks are visualized, and no evidence of pulmonary hypertension. No evidence of diet-related cardiomyopathy; however, a diet change remains the conservative recommendation. Finally, the ECG is unremarkable with a normal sinus rhythm.

These findings would suggest an increased VHS is a normal variant. These films should be used as a baseline of future comparison.

Monitor for development of a heart murmur, cough, labored breathing, exercise intolerance or collapse episodes.

A recheck echocardiogram is recommended should a significant murmur develop, or signs of cardiac compromise be noted in the future.

IMAGES

The information and recommendations provided are based on the images presented by the referring veterinarian. No evaluation can be communicated regarding pathology that was not visible in the image/video clips provided.

Thank you for this referral. If the clinical or image interpretation does not parallel your findings or if I can be of any further assistance, please contact me.

Maggie Machen Lamy, DVM
Diplomate of the American College of Veterinary Internal Medicine (Cardiology)
 info@sonopath.com